



# Treatment of deep corneal ulcers with porcine small intestinal submucosa using a modified surgical technique in dogs

Andrea Steinmetz  | Lars F.H. Theyse

Department of Small Animals, University of Leipzig, Leipzig, Germany

## Correspondence

Andrea Steinmetz, Department of Small Animals, Ophthalmology Service, College of Veterinary Medicine, University of Leipzig, An den Tierkliniken 23, 04103 Leipzig, Germany.  
Email: steinmetz@kleintierklinik.uni-leipzig.de

## Funding information

Universität Leipzig

## Abstract

Treatment of deep corneal ulcers using small intestinal submucosa (SIS) without corneal sutures in combination with a third eyelid flap seems a promising technical modification. Advantages are a reduction in surgery time and no additional damage of healthy corneal tissue.

## KEYWORDS

brachycephalic ocular syndrome, deep corneal ulcer, dog, modified technique, small intestinal submucosa, third eyelid flap

## 1 | INTRODUCTION

Deep corneal ulcers were treated with small intestinal submucosa (SIS) using a modified surgical technique in four brachycephalic dogs. SIS was contoured to fit the exact size of the defect without suturing the graft to the cornea. A temporary third eyelid flap was used to stabilize the SIS initially.

Ulcerative keratitis has a vast range of causes in dogs.<sup>1</sup> Brachycephalic breeds have the highest prevalence of corneal ulcers<sup>2</sup> with a twenty times higher likelihood to be affected than non-brachycephalic dogs.<sup>3,4</sup> The predisposing factors include macroblepharon, shallow orbits with subsequent lagophthalmos, medial canthal entropion, trichiasis, tear film deficits, and reduced corneal sensitivity. These factors are collectively known as brachycephalic ocular syndrome (BOS).<sup>4</sup> In one study, most of the mean values of ocular surface diagnostic tests were lower in brachycephalic compared to non-brachycephalic dogs.<sup>5</sup>

Progressive deep corneal ulcers in the dog are potentially vision- and globe-threatening. Surgical intervention is indicated in deep corneal ulceration, when depth of the corneal lesion is 50% of the corneal thickness or deeper.<sup>1</sup> To improve healing, replace lost tissue and to achieve a stable and best

possible visual outcome autologous, allogeneic and xenogeneic grafts and biomaterials have been used. Xenogeneic grafts and biomaterials can be considered if autologous<sup>6</sup> or allogeneic<sup>7</sup> corneal grafting is not possible due to restrictions in defect size or availability. Porcine bladder acellular matrix (ACell), amniotic membranes, bovine pericardium, and porcine small intestinal submucosa (SIS) are biomaterials which have been applied successfully in treating canine deep corneal defects.<sup>8-16</sup> Typically, these graft materials are stabilized at the edge of the defect to the intact peripheral corneal tissue using sutures. The aim of this study was to demonstrate a modified technique not requiring corneal suturing reducing the duration of the surgical procedure and avoiding additional trauma to healthy corneal tissue.

## 2 | CASE HISTORY AND EXAMINATION

Four middle-aged brachycephalic dogs were presented with deep corneal ulcers. Data concerning breed, gender, age, and affected eye are listed in Table 1. A general clinical

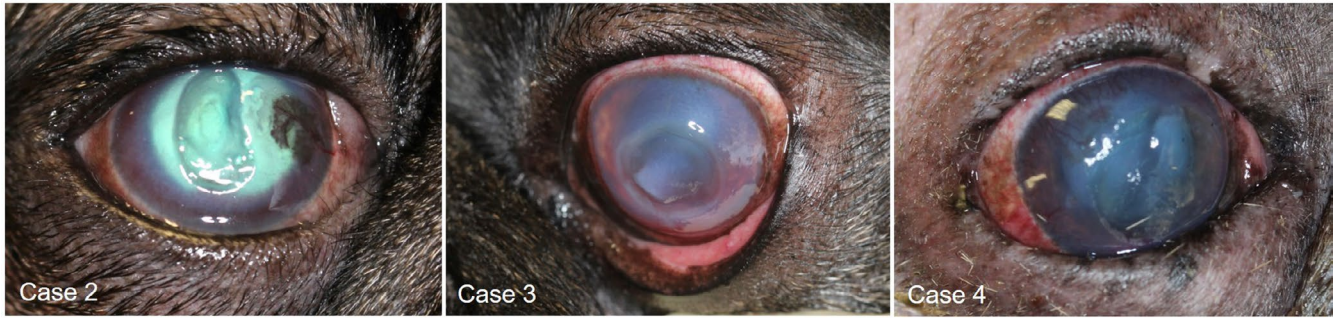This is an open access article under the terms of the Creative Commons Attribution-NonCommercial-NoDerivs License, which permits use and distribution in any medium, provided the original work is properly cited, the use is non-commercial and no modifications or adaptations are made.

© 2020 The Authors. *Clinical Case Reports* published by John Wiley & Sons Ltd.

**TABLE 1** Overview of the data of the examined patients, characteristics of the defects, therapy, and outcome

Case	Breed Gender/Age (y)/Eye	Characteristics of the ulcer	Cause	Bacteriological investigation / Sensitivity to antibiotics	Duration of third eyelid flap application (d)	Confirmed epithelial healing (d)	Final examination (d)	Vision / Transparency at latest examination
1	French Bulldog M / 8 y / Os	deep stromal (> 50%), melting, diameter: 12 mm	bite injury three weeks ago; BOS	Streptococcus canis / sensitive to Cefalexine, intermediate to Moxifloxacin	24	24	24	cotton ball / ring of vessels and fibrosis with clear center, small amount of pigmentation in the lateral quadrant
2	Pug M / 5 y / Od	deep stromal (> 80%), central, diameter: 9 mm	suspected injury to plant; BOS	n.e.	26	26	26	cotton ball / semicircle of vessel, subtle pigmentation laterally, clear center
3	French Bulldog M / 6 y / Os	deep stromal (>50%), melting, central, diameter: 10 mm	unobserved trauma; BOS	Enterobacter cloacae / resistant to Cefalexine, sensitive to Moxifloxacin; Streptococcus canis / sensitive to Cefalexine, intermediate to Moxifloxacin	24	24	48	cotton ball / small amount of fibrosis and pigmentation in the medio- ventral quadrant
4	French Bulldog M / 7 y / Od	deep stromal (>50%), central, Diameter: 11 mm	distichiasis; BOS	negative	22	22	50	cotton ball / very subtle ring of fibrosis and pigmentation

Abbreviations: BOS, Brachycephalic ocular syndrome; M, male; n.e., not examined; Od, right eye; Os, left eye.



**FIGURE 1** Deep corneal ulcers in three dogs with BOS

examination was performed revealing loud breathing, stertor, and stridor in all four dogs.

Owners confirmed exercise and heat intolerance in all four dogs. These findings were consistent with severe respiratory brachycephalic syndrome.<sup>17</sup> Slit lamp (SL 17, Kowa company Ltd.) examination showed deep corneal ulcer in one eye consistent with BOS (Figure 1). Characteristics and causes of the ulcer, detected bacteria, their sensitivity to antibiotics, duration of third eyelid flap application, healing time, vision, and transparency of the cornea at time during the last examination are listed in Table 1 too.

Corneal bacteriological swab samples were taken in three cases. Bacterial swabs were positive with a mono-culture of *Streptococcus canis* in case 1 and with *Streptococcus canis* and *Enterobacter cloacae* in case 3. From the corneal swab sample in one deep melting ulcer (case 4), no bacteria could be isolated.

### 3 | TREATMENT

Topical therapy was started with Moxifloxacin eye drops (Vigamox<sup>®</sup>, Alcon Pharma GmbH) six times in day, atropine eye drops (Atropin-POS 1%<sup>®</sup>, Ursapharm GmbH) s.i.d. and autologous serum eye drops five times per day. Systemic cefalexin (Cefaseptin<sup>®</sup>, Vetoquinol) 20 mg/kg b.i.d. and 2 mg/kg robenacoxib (Onsior<sup>®</sup>, Elanco) s.i.d were administered orally.

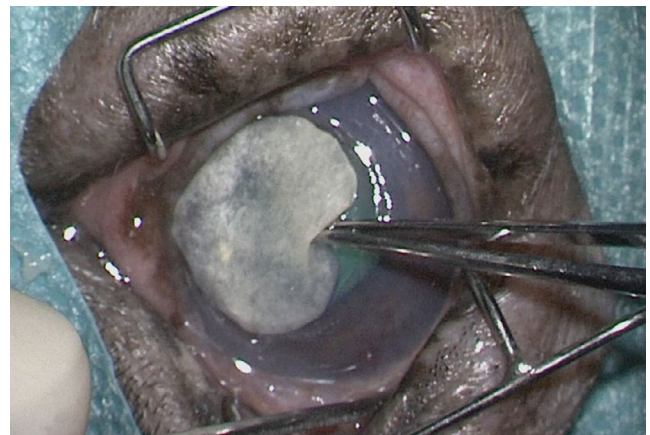
Anesthesia was induced intravenously with 0.5 mg/kg diazepam (Faustan<sup>®</sup>, Temmler Pharma) and 0.5 mg/kg levomethadone in a fixed combination with 0.025 mg/kg fenipramide (L-Polamivet<sup>®</sup>, Intervet). Anesthesia was maintained via endotracheal intubation with 1% isoflurane (Isofluran CP, CP Pharma) dissolved in oxygen at a flow rate of 10 ml/kg/min.

After placing the dog in dorsal recumbency, the head was stabilized in a vacuum bag. The eye was aseptically prepared for surgery, and a Barraquer eyelid speculum was inserted. The ulcer bed was carefully prepared and collagenolytic tissue was removed before the SIS was placed. A 15 mm SIS disk (Vetrix<sup>®</sup> BioSIS ECM, Vetrix) was rehydrated in

balanced salt solution (BSS<sup>®</sup>, Serag Wiessner) and trimmed to fit the exact size of the ulcer thus filling the defect completely (Figure 2). The SIS graft was temporarily stabilized using a third eyelid flap. The flap was placed by horizontal mattress suture pattern (three stitches) in the upper eyelid with Nylon-suture 4-0 (Ethilon<sup>®</sup>, Ethicon). Care was taken not to dislodge the SIS graft out of the defect during this procedure (Figure 3). Topical medication was continued with Moxifloxacin and Atropine applied directly onto the nictitating membrane. Cefalexin and robenacoxib were prescribed for two weeks and four days, respectively. The third eyelid flap was left in place for a minimum of three weeks. The owners were instructed to look for purulent discharge and signs of pain during this period. The patients were re-examined at time of releasing the third eyelid flap (all cases), five days after releasing the third eyelid flap (one case) and three weeks after release (two cases) (see table 1).

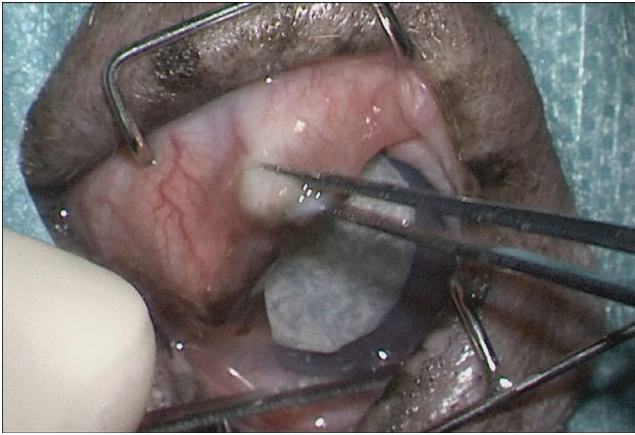
### 4 | OUTCOME

There were no complications during the three-week period with the third eyelid flap without any signs of pain or purulent discharge.



**FIGURE 2** SIS graft contoured to exact size filling the corneal defect completely





**FIGURE 3** Application of the third eyelid flap

At the time of releasing the third eyelid flap, corneal defects showed neovascularization and complete epithelial healing (Figure 4). All dogs could see a falling cotton ball at this time (see Table 1). Regression of the vascularization and increased corneal transparency was clearly noted six weeks postoperatively in cases 3 and 4 (Figure 5). Cases 1 and 2 were lost for further follow-up.

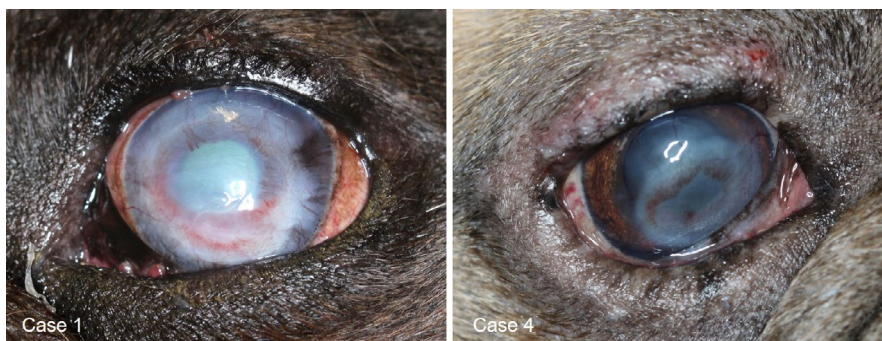## 5 | DISCUSSION

The advantages of using SIS grafts for surgical treatment of deep or full thickness corneal ulcers are good mechanic support, corneal transparency, and maintenance of vision in

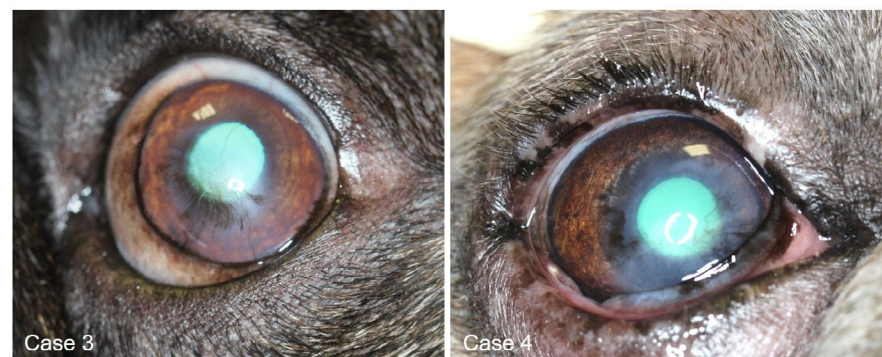most cases.<sup>11,15,16</sup> The xenogeneic material replaces missing tissue and serves for regeneration. SIS has been used successfully for surgical therapy of corneal defects in domestic and zoo animals.<sup>11,12,15,18,19</sup> The grafts were applied either alone<sup>8,11,18,19</sup> or in combination with covering by a conjunctival flap<sup>12</sup> or with temporary lateral tarsorrhaphy<sup>11</sup> or with a temporary third eyelid flap.<sup>16</sup> All these SIS grafts were placed in the defect and sutured in the peripheral intact cornea tissue. Corneal suturing is technically demanding but also additionally damaging the cornea. The technique which was described in this case report was without additional damage of healthy corneal tissue.

Furthermore, this study consisted of cases in which a therapeutic compromise had to be found: Therapeutic management was limited due to financial restraints (cases 2 and 4), compliance of the owners (cases 1 and 2) and anesthetic restraints due to the severe respiratory brachycephalic syndrome (all cases). Surgical therapy was imperative in all four cases because of the depth of the ulcers. The compromise was to use SIS as scaffold and for replacing missing tissue without suturing in combination with a third eyelid flap for providing bandage and mechanical stability. This resulted in a reduction of the surgery time which is the second advantage of the modified technique.

Most commonly isolated bacteria in infected corneal ulcers are *Staphylococcus* and *Streptococcus* spp.<sup>20</sup> In this study, *Streptococcus canis* could be detected in two cases. In contrast, the corneal swab sample of the melting ulcer in case 4 was negative.



**FIGURE 4** Corneal healing immediately after releasing of the third eyelid flap



**FIGURE 5** Excellent corneal transparency six weeks postoperatively

While waiting for the antibiotic test results, all ulcers in this study were treated with systemic antibiotics and topical application of preservative free antibiotic eyedrops before and after surgery.

The main disadvantage of the third eyelid flap could be the deficiency of direct monitoring the progression of corneal healing.<sup>21</sup> On the contrary, the third eyelid flap is superior to a temporary lateral tarsorrhaphy for full coverage of the non-stabilized SIS graft.

In addition, complications can be monitored by assessing ocular discharge and pain. These symptoms could not be seen in all four cases.

Further limitations of the study were the small sample size and the short follow-up time in two cases. Studies with more patients and a comparison group for further research into this technique should be performed in future. But the first results presented in this case report are promising that the modified surgical technique may be useful in very selected cases because it makes the procedure easier and faster. Further advantages are a reduction in surgery time and no additional damage of healthy corneal tissue. In all cases of this report, the cosmetic and visual outcome was very good to excellent.

## ACKNOWLEDGMENTS

We acknowledge the support from the German Research Foundation (DFG) and funding from the University within the program of Open Access Publishing.

## CONFLICT OF INTEREST

There is no conflict of interest.

## AUTHOR CONTRIBUTIONS

Author 1: surgeon, main author, composing, and writing of the manuscript, figures. Author 2: composing and writing of the manuscript.

## ETHICAL APPROVAL

The study included patients for whom the presented surgical technique was done as part of therapy.

The owners agree to the publication of the data and photographs. The local requirements have been complied with.

## DATA AVAILABILITY STATEMENT

All clinical data are available in the medical records and with the corresponding author.

## ORCID

Andrea Steinmetz  <https://orcid.org/0000-0001-7256-6837>

## REFERENCES

1. Gelatt KN, Gilger BC, Kern TJ, eds. *Veterinary Ophthalmology: Two Volume Set*. 5. Aufl. s.l.: Wiley-Blackwell; 2013.
2. O'Neill DG, Lee MM, Brodbelt DC, Church DB, Sanchez RF. Corneal ulcerative disease in dogs under primary veterinary care in England: epidemiology and clinical management. *Canine Genet Epidemiol*. 2017;4:5.
3. Packer RMA, Hendricks A, Burn CC. Impact of facial conformation on canine health: corneal ulceration. *PLoS One*. 2015;10(5):e0123827.
4. Plummer CE. Addressing Brachycephalic Ocular Syndrome in the dog. *Today's Veterinary Practice*. 2015(March/April):20-25.
5. Bolzanni H, Oriá AP, Raposo ACS, Sebbag L. Aqueous tear assessment in dogs: impact of cephalic conformation, inter-test correlations, and test-retest repeatability. *Vet Ophthalmol*. 2020;23(3):534-543.
6. Brightman AH, McLaughlin SA, Brogdon JD. Autogenous lamellar corneal grafting in dogs. *J Am Vet Med Assoc*. 1989;195(4):469-475.
7. Lacerda RP, Pena Gimenez MT, Laguna F, Costa D, Rios J, Leiva M. Corneal grafting for the treatment of full-thickness corneal defects in dogs: a review of 50 cases. *Vet Ophthalmol*. 2017;20(3):222-231.
8. Balland O, Poinard A-S, Famose F, et al. Use of a porcine urinary bladder acellular matrix for corneal reconstruction in dogs and cats. *Vet Ophthalmol*. 2016;19(6):454-463.
9. Dulaurent T, Azoulay T, Gouille F, et al. Use of bovine pericardium (Tutopatch(R)) graft for surgical repair of deep melting corneal ulcers in dogs and corneal sequestra in cats. *Vet Ophthalmol*. 2014;17(2):91-99.
10. Kim JY, Choi YM, Jeong SW, Williams DL. Effect of bovine freeze-dried amniotic membrane (Amnisite-BA) on uncomplicated canine corneal erosion. *Vet Ophthalmol*. 2009;12(1):36-42.
11. Barachetti L, Zanni M, Stefanello D, Rampazzo A. Use of four-layer porcine small intestinal submucosa alone as a scaffold for the treatment of deep corneal defects in dogs and cats: preliminary results. *Vet Rec*. 2020;186(19):e28.
12. Bussieres M, Krohne SG, Stiles J, Townsend WM. The use of porcine small intestinal submucosa for the repair of full-thickness corneal defects in dogs, cats and horses. *Vet Ophthalmol*. 2004;7(5):352-359.
13. Chow DWY, Westermeyer HD. Retrospective evaluation of corneal reconstruction using ACell Vet alone in dogs and cats: 82 cases. *Vet Ophthalmol*. 2016;19(5):357-366.
14. Costa D, Leiva M, Sanz F, et al. A multicenter retrospective study on cryopreserved amniotic membrane transplantation for the treatment of complicated corneal ulcers in the dog. *Vet Ophthalmol*. 2019;22(5):695-702.
15. Gouille F. Use of porcine small intestinal submucosa for corneal reconstruction in dogs and cats: 106 cases. *J Small Animal Pract*. 2012;53(1):34-43.
16. Vanore M, Chahory S, Payen G, Clerc B. Surgical repair of deep melting ulcers with porcine small intestinal submucosa (SIS) graft in dogs and cats. *Vet Ophthalmol*. 2007;10(2):93-99.
17. Roedler FS, Pohl S, Oechtering GU. How does severe brachycephaly affect dog's lives? Results of a structured preoperative owner questionnaire. *Vet J*. 2013;198(3):606-610.
18. Steinmetz A, Bernhard A, Minkwitz C, Böttcher D. Chirurgische Versorgung einer Hornhautperforation bei einem Zebra. *Der Ophthalmol*. 2019;116(10):967-969.
19. Steinmetz A, Moerke-Schindler T. Chirurgische Versorgung eines perforierten Korneaukulus bei einem Kongo-Graupapagei (*Psittacus erithacus erithacus*). *Kleintierpraxis*. 2017;62(6):366-372.

20. Fentiman KE, Rankin AJ, Meekins JM, Roush JK. Effects of topical ophthalmic application of 0.5% proparacaine hydrochloride on aerobic bacterial culture results for naturally occurring infected corneal ulcers in dogs. *J Am Vet Med Assoc.* 2018;253(9): 1140-1145.
21. Maggs DJ, Miller PE, Ofri R, Slatter DH. *Slatter's Fundamentals of Veterinary Ophthalmology*, 5th edn. St. Louis, MO: Elsevier; 2013.

**How to cite this article:** Steinmetz A, Theyse LFH. Treatment of deep corneal ulcers with porcine small intestinal submusosa using a modified surgical technique in dogs. *Clin Case Rep.* 2020;00:1–6. <https://doi.org/10.1002/ccr3.3661>